Endoscopic Management of Premalignant/Malignant Colorectal Lesions

Mohammad Minakari,MD,IUMS

1969 – First Endoscopic Polypectomy

- Hans Peter Deyhle (Germany)
- Birth of therapeutic endoscopy



Early Advances (1970s–1980s)

- Flexible scopes
- Injection therapy development
- Early mucosal resection attempts

1984 – First EMR (Injection-Lift Technique)

- Hiromi Hosokawa (Japan)
- Submucosal saline injection created the mucosal lift

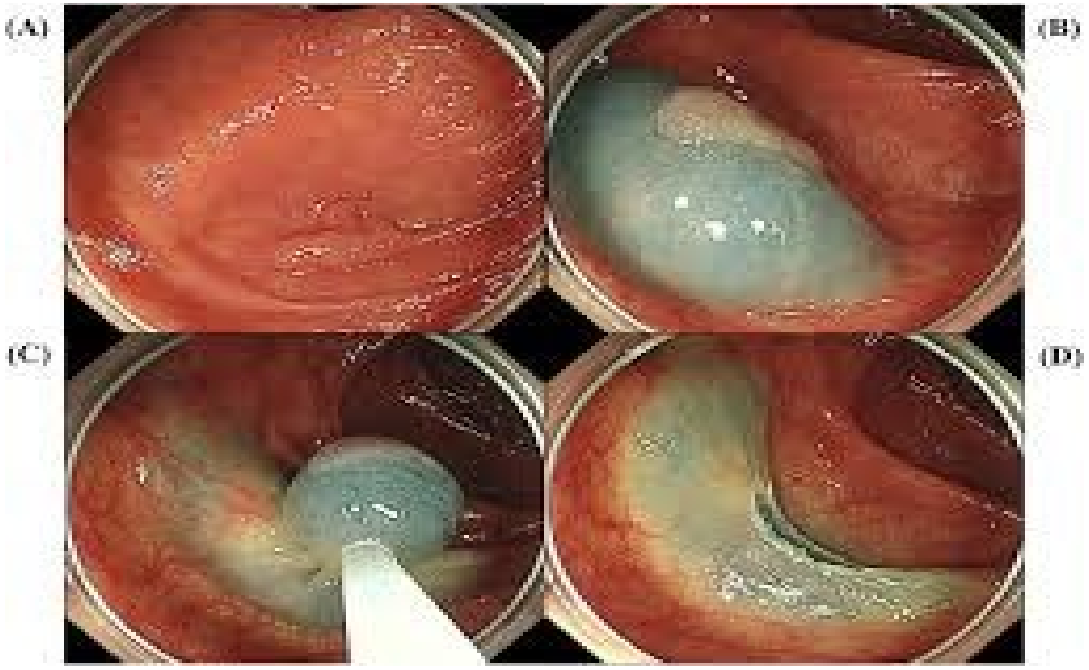

1992 – Cap-Assisted EMR (EMR-C)

- Wolfgang Rösch (Germany)
- Standardized EMR for flat and sessile lesions

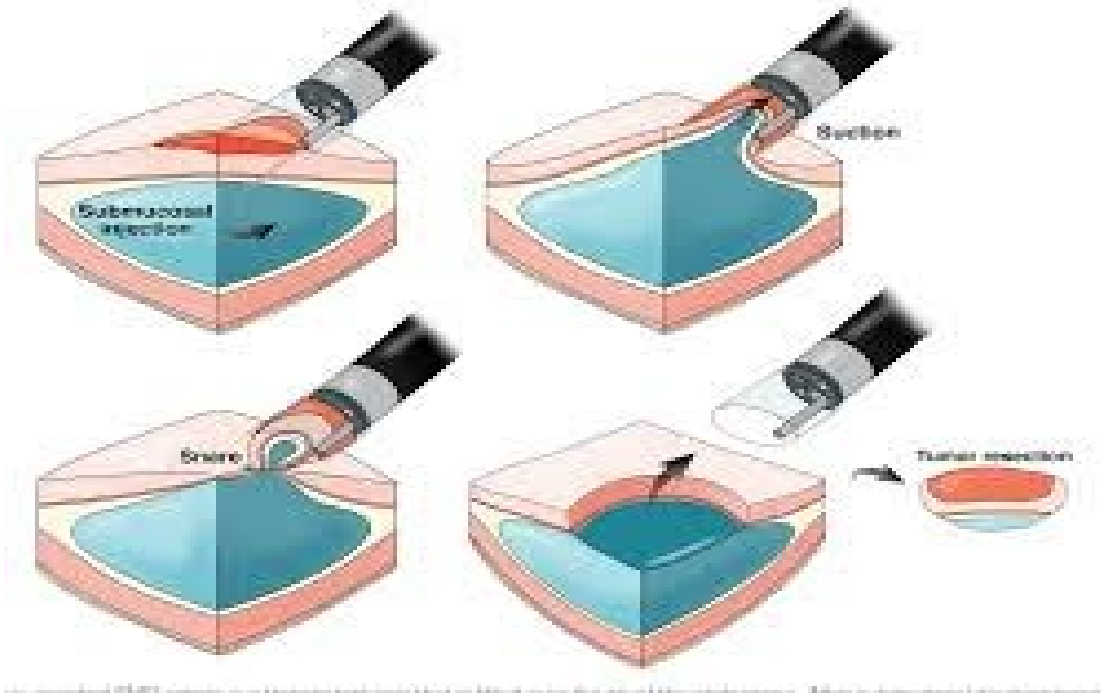

1990s – Evolution of Therapeutic Endoscopy

- Snare technology improvements
- Better electrosurgical units
- Improved visualization

1999 – First ESD

- Hironori Ono (Japan)
- First true submucosal dissection for early gastric cancer

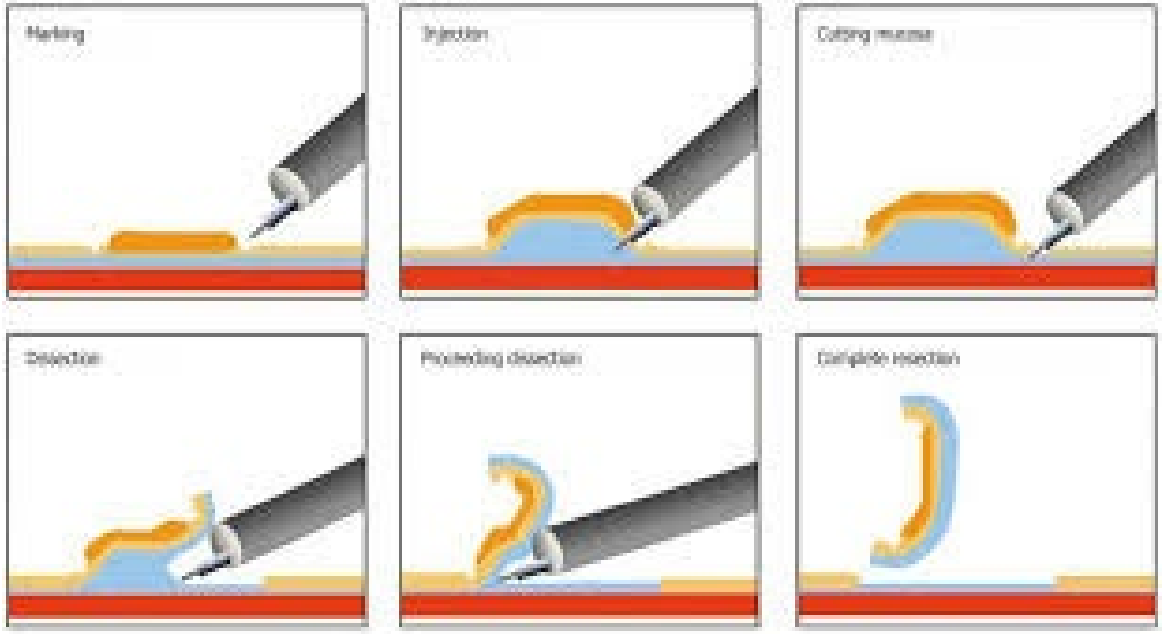

Early 2000s – Expansion of ESD

- Inoue: Esophageal ESD (2000–2003)
- Japanese centers: Colorectal ESD (2003–2005)

Advantages of ESD

- En bloc resection
- Lower recurrence vs EMR
- Curative for early GI cancers

Technical Evolution of ESD

- Dual knife, IT knife, Hook knife
- Better hemostasis tools
- High-definition endoscopy

Global Expansion (2010–2025)

- Formal training programs
- Hybrid ESD for beginners
- Traction devices

Introduction to EFTR

- Endoscopic Full-Thickness Resection
- Developed 2015–present
- Allows resection beyond mucosa/submucosa

EFTR – Key Concepts

- Resection with defect closure
- Useful for deep submucosal tumors
- Full-thickness wall removal

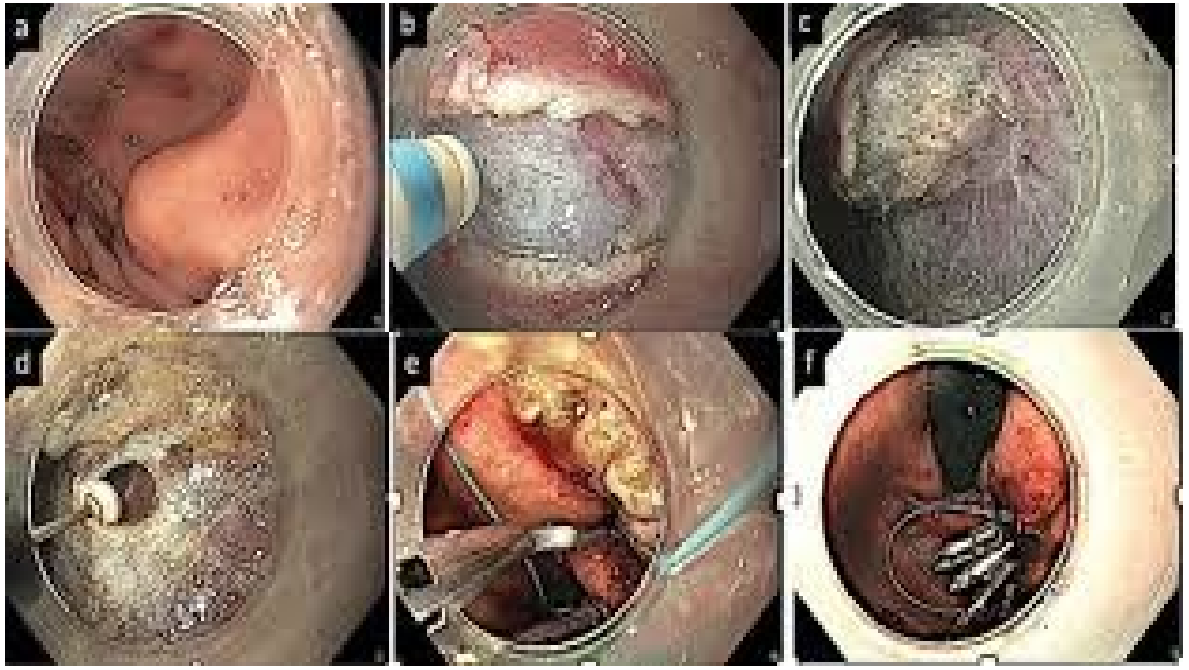

Devices for EFTR

- FTRD (Full Thickness Resection Device)
- Over-the-scope clip–based systems
- Hybrid NOTES approaches

Robotic-Assisted ESD – Introduction

- 2020 onwards
- Creation of robotic platforms to improve precision

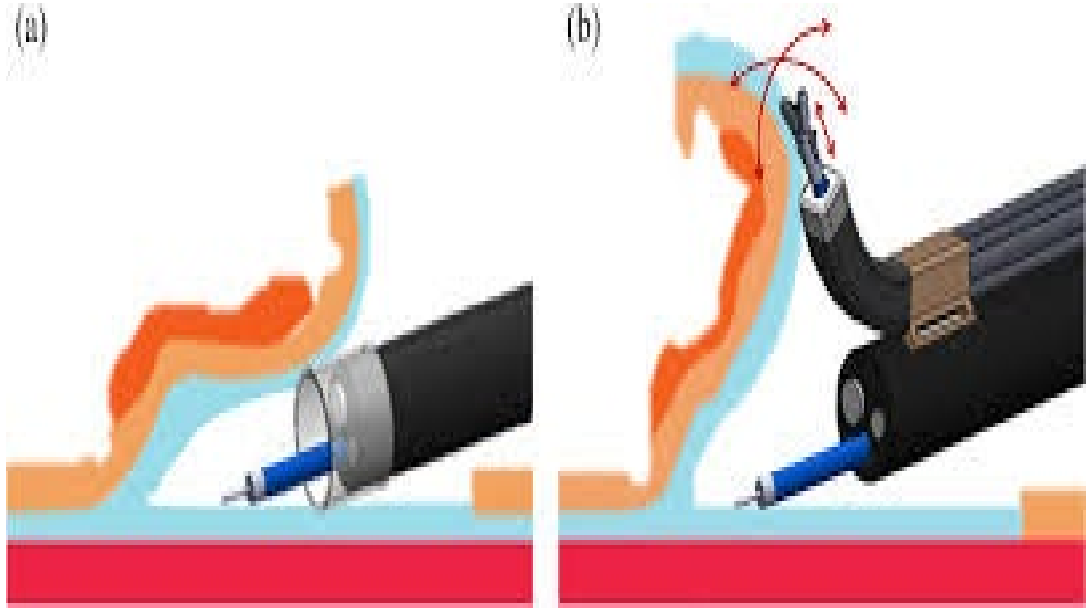

Robotic-Assisted ESD – Benefits

- Enhanced dexterity
- Stability of dissection
- Potential reduction in perforation risk

Future Directions

- AI-assisted dissection
- Real-time margin analysis
- Integrated robotic-EFTR systems

Basic principles of endoscopic resection

-**Careful evaluation of the lesion**

-Determine appropriate procedure for appropriate patient

-Prepare equipments

-Proper technic of injection/resection/electrosurgery

-prevention of complications

What do you need to know before resection ?

- Risk of malignancy
- Risk of LN posiitivity

Malignant Polyp

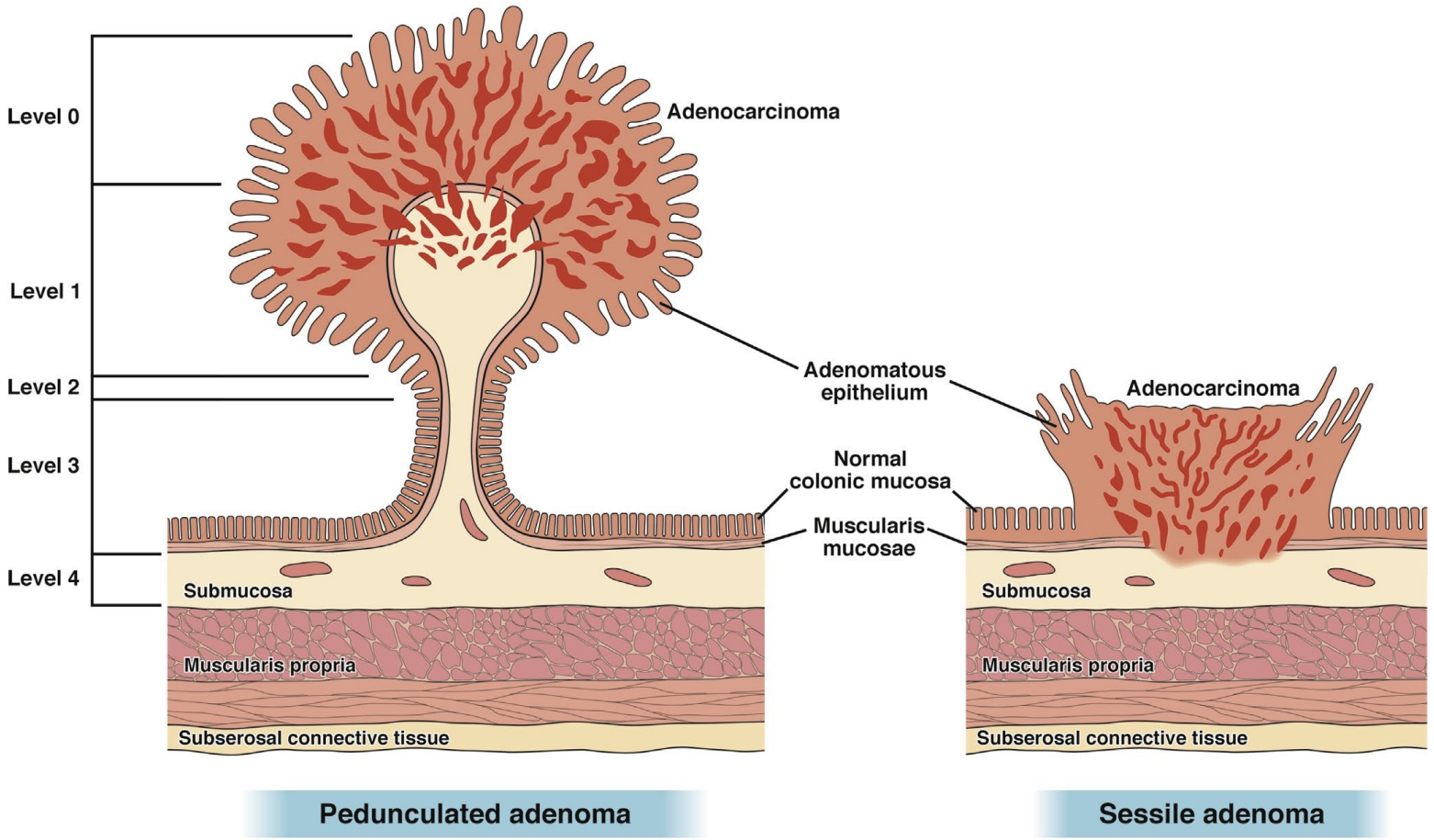

Deep Submucosal Invasion

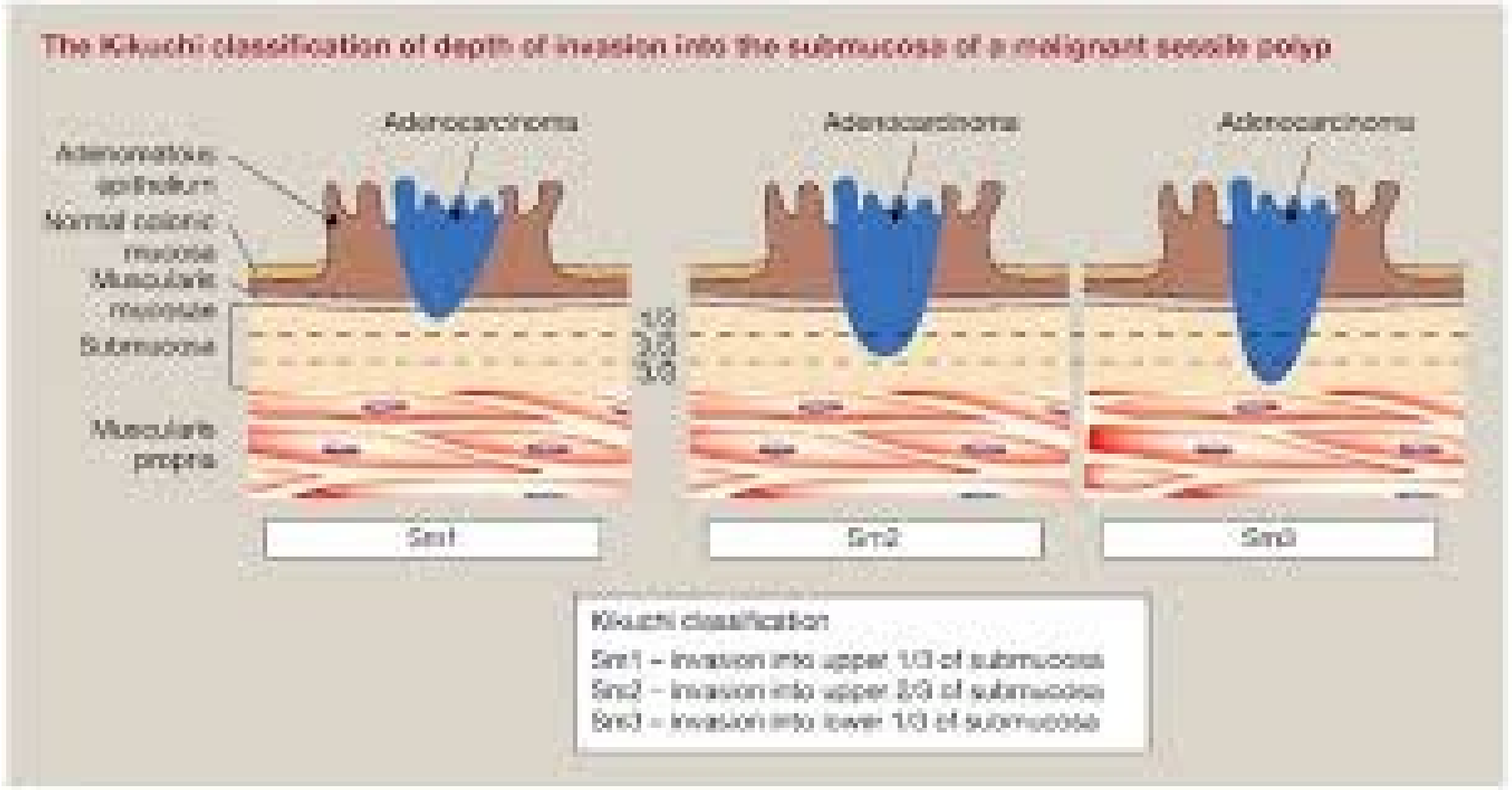

Paris Classification

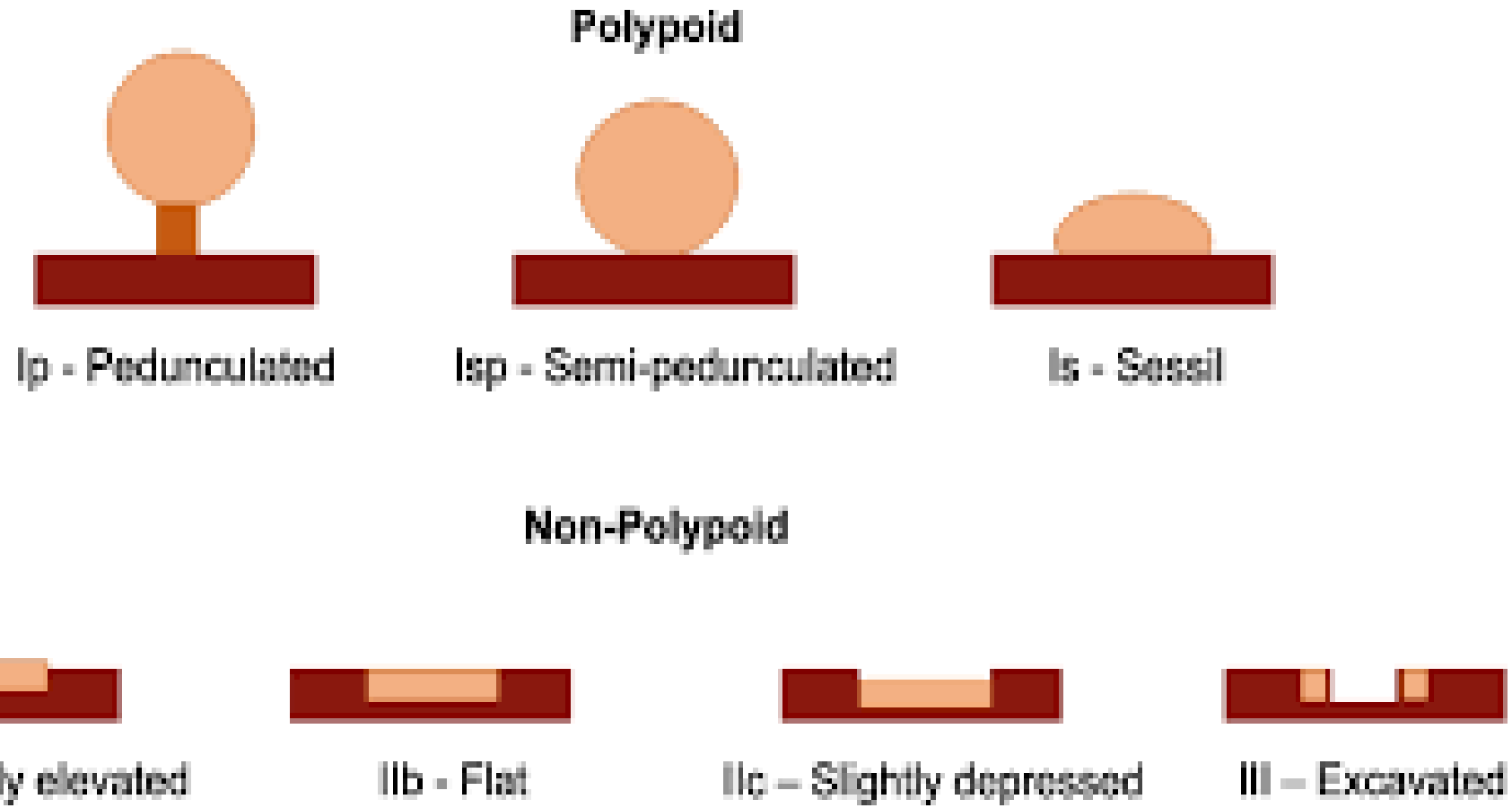

NICE CLASSIFICATION

	Type 1	Type 2	Type 3
Color	Same or lighter than background	Browner relative to background (verify that color arises from vessels)	Brown to dark brown relative to background, sometimes patchy whiter areas
Vessels	None or isolated lacy vessels coursing across the lesion	Brown vessels surrounding white structures	Has area(s) with markedly distorted or missing vessels
Surface pattern	Dark or white spots of uniform size, or homogeneous absence of pattern	Oval, tubular, or branched white structures surrounded by brown vessels	Areas with distortion or absence of pattern
Most likely pathology	Hyperplastic	Adenoma	Deep submucosally invasive cancer
			

J-NET Classification

Japanese NBI Expert Team (JNET) classification

NBI	Type 1	Type 2A	Type 2B	Type 3
Vessel pattern	• Invisible [1]	• Regular caliber • Regular distribution [2] (meshed/spiral pattern)	– Variable caliber – Irregular distribution	– Loose vessel areas – Interruption of thick vessels
Surface pattern	• Regular dark or white spots • Similar to surrounding normal mucosa	• Regular (tubular/branched/papillary)	– Irregular or obscure	– Amorphous areas
Most likely histology	Hyperplastic polyp/ Sessile serrated polyp	Low-grade intramucosal [4] neoplasia	High-grade intramucosal [5] neoplasia/ Superficial [3] submucosal invasive cancer	Deep submucosal invasive cancer
Examples				

• 1. If visible, the pillar in the lesion is similar to surrounding normal mucosa.
• 2. Microvessels are often distributed in a puncture pattern and not redundant reticular or spiral vessels may not be observed in depressed lesions.
• 3. Deep submucosal invasive cancer may be included.
• 4. Low-grade intramucosal neoplasia: low-grade dysplasia.
• 5. High-grade intramucosal neoplasia: high-grade dysplasia.

KUDO-PIT PATTERN

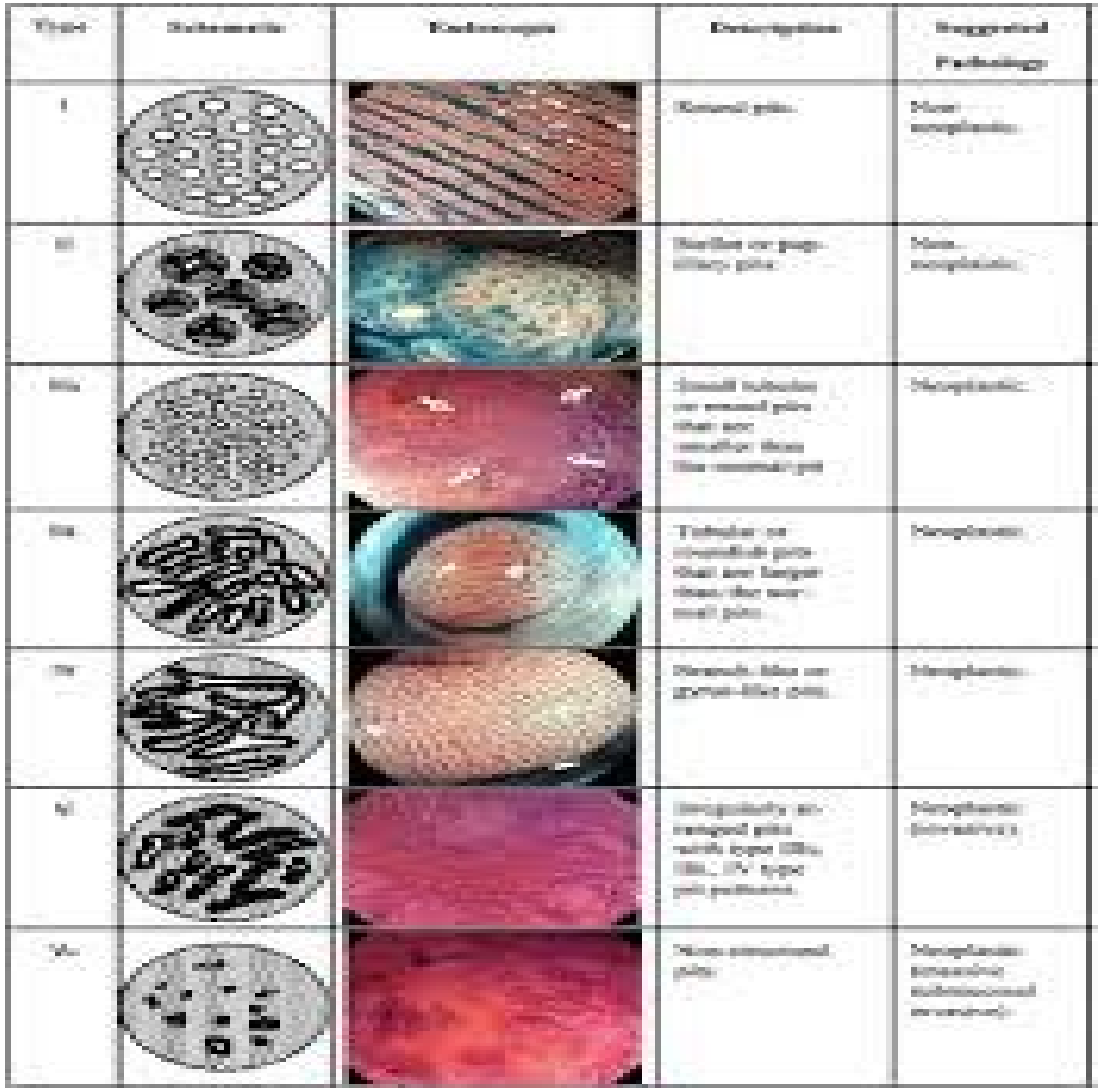

Rectal EUS

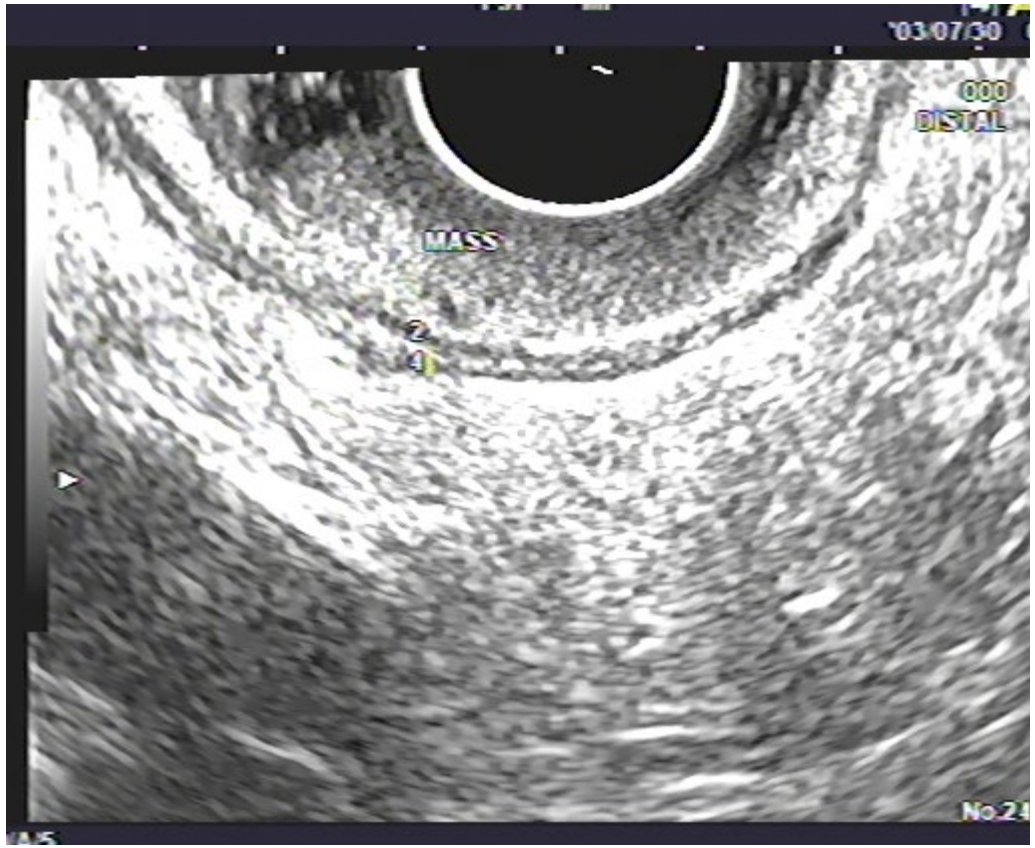

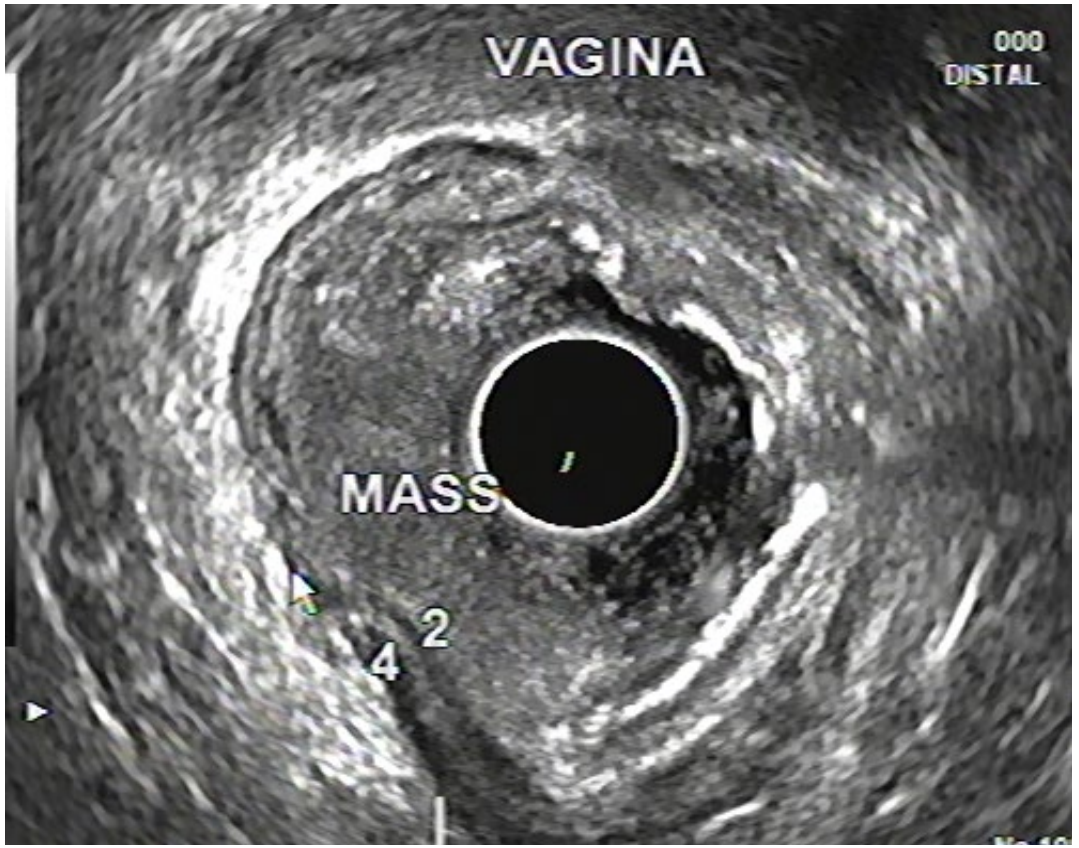

Comparison of MRI vs EUS for Local Staging of Rectal Cancer

Parameter	MRI	EUS
Best for	Assessing mesorectal fascia, T3–T4 tumors, and N staging	Assessing T1–T2 depth of wall invasion
Sensitivity (T-staging)	≈ 75–90%	≈ 85–95%
Specificity (T-staging)	≈ 70–85%	≈ 80–90%
Limitations	Less accurate for early (T1–T2) lesions	Limited penetration for large or stenotic tumors

Sources: AJR 2014; Radiology 2019; EJSO 2021
— pooled meta-analyses of MRI and EUS accuracy for rectal cancer staging.

Diagnostic Accuracy for Submucosal Invasion in Rectal Polyps

Modality	Sensitivity (%)	Specificity (%)
Endoscopic Ultrasound (EUS)	≈ 85–90	≈ 85–90
High-Resolution MRI (Rectal)	≈ 70–94	≈ 74–91
Colonoscopy (Surface Morphology / NBI / Chromoendoscopy)	≈ 60–90	≈ 90–96

Data based on pooled estimates from recent meta-analyses and major studies (Karger 2021, AJR 2014, GIE 2020).

Non-Lifting Sign

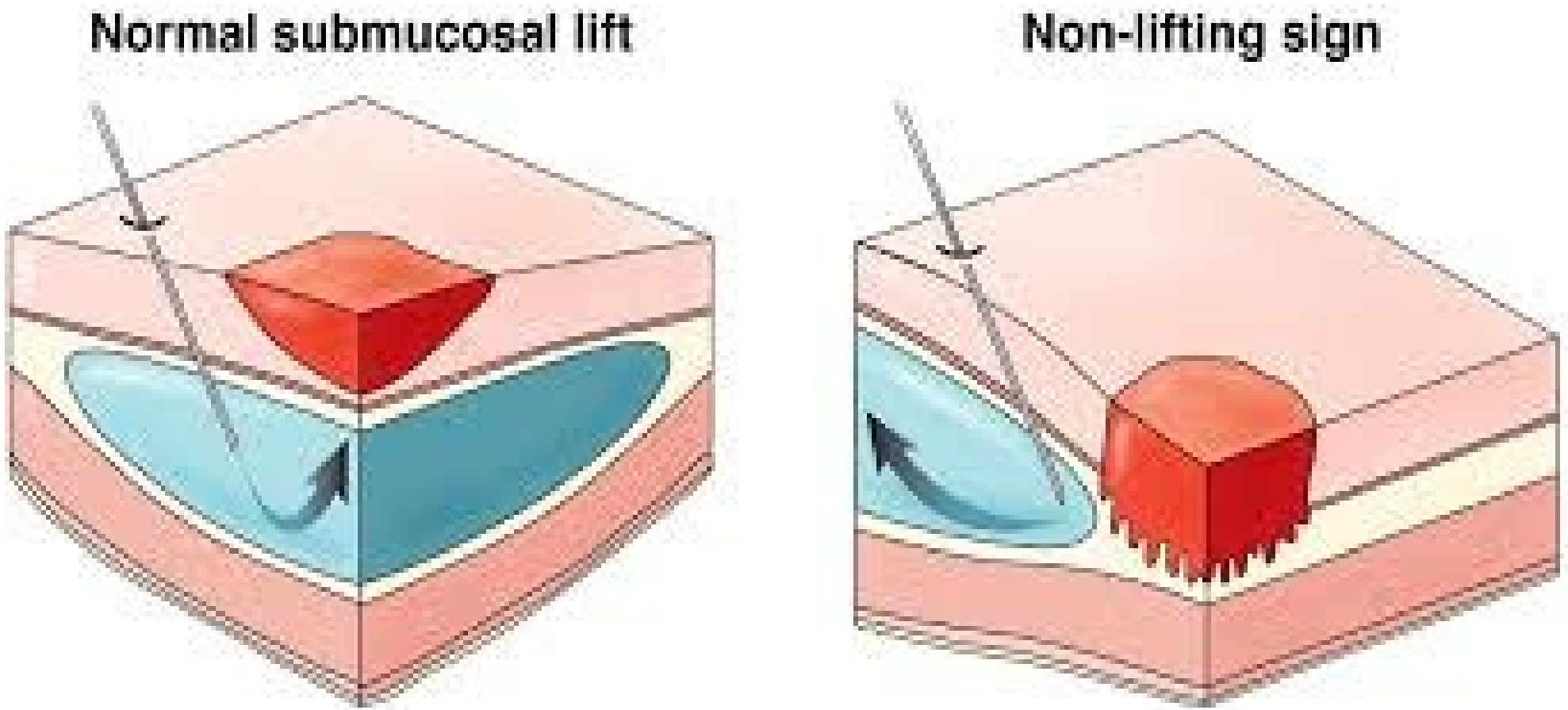

Depth of Invasion and LN Risk

- SM1 (<1 mm): ~1% LN risk
- SM2 (1–2 mm): 5–8% LN risk
- SM3 (>2 mm): 10–20% LN risk

High-risk histology increasing LN metastasis:

- Lymphovascular invasion (LVI+)
- Poor differentiation
- High tumor budding
- Positive vertical margin

Choosing the Endoscopic Technique

SM1 (<1 mm):
• EMR en-bloc if lesion ≤20 mm
• ESD if >20 mm or en-bloc required
→ Endoscopic cure usually adequate

SM2 (1–2 mm):
• ESD preferred for en-bloc histology
→ Surgery only if high-risk pathology present

SM3 (>2 mm):
• Endoscopic resection not curative
• ESD only if patient is high-risk for surgery
→ Standard treatment = segmental colectomy + lymphadenectomy

Contraindications to Endoscopic Resection

Avoid endoscopic resection when deep invasion is suspected:

- Depressed morphology (Paris 0-IIc)
- Non-lifting sign in untreated lesions
- Ulceration
- NICE type 3 / JNET type 3 patterns
- Marked surface or vascular irregularity

→ Direct referral for surgery recommended

Take Home Message

- Endoscopic resection for colorectal premalignant/malignant lesions is safe & effective with less morbidity /mortality than surgery
- Careful evaluation of the polyp/tumor is the most important step for deciding the best modality for resection
- If you think endoscopic resection is possible ,do it completely or don’t do anything ,just refer to intervention expert center

THANK YOU

